

Abnormal Fetal Profile at First-trimester Ultrasound Scan Complicated by Severe Polyhydramnios at the Second Half of Pregnancy

Ana Portela Carvalho*, Catarina Estevinho, Maria Coelho, Juliana Rocha, Carla Marinho, Graça Rodrigues

Department of Obstetrics and Gynaecology, Centro Hospitalar do Tâmega e Sousa, Penafiel, Porto, Portugal

SECTION 2 – ANSWER

CASE REPORT

A 37-year-old pregnant woman was referred to our hospital at 9 weeks of gestation with a history of previous medical termination of pregnancy in the context of prenatal diagnosis of trisomy 21. In the third pregnancy, first-trimester ultrasound (US) revealed a fetus with a gestational age of 12 weeks and 6 days with a suspicion for fetal micrognathia but no other morphologic abnormalities [Figures 1 and 2]. The first-trimester combined screening had reduced the risk for aneuploidies. The performance of invasive testing was offered, but the couple refused. At the mid-trimester US scan, performed at 20 weeks and 5 days of gestation, the fetus had normal amniotic fluid index and adequate biometric parameters. Fetal facial profile was abnormal, suggesting mandibular hypoplasia and glossoptosis [Figures 3 and 4]. Morphology of the upper lip was normal [Figure 5]. There were no other sonographic anomalies identified. Screening for gestational diabetes was negative, and there was no evidence for maternal TORCH (Toxoplasmosis, Other [syphilis, varicella-zoster, parvovirus B19], Rubella, Cytomegalovirus, and Herpes infections) seroconversion. Detailed fetal echocardiography was normal. At 32 weeks and 5 days, US revealed a mild polyhydramnios that progressively increased in severity. At 36 weeks, the fetus had an amniotic fluid index of 35.2 cm (deepest pool of 10.3 cm [Figure 6]) and was growing in the 61st centile. A detailed review of fetal anatomy highlighted a prominent upper lip and receding chin in the midsagittal view of the face [Figures 7-9]. A controlled induction of labor was initiated at 37 weeks. An emergent C-section was performed because of placental abruption, and a male newborn with 2760 g, Apgar index 5/7/8 was delivered.

INTERPRETATION

The early sonographic diagnosis of isolated microretrognathia in association with the US finding of severe polyhydramnios in the third trimester of pregnancy presented in this clinical case is highly suggestive of Pierre Robin sequence (PRS). PRS is a rare condition that affects between 1/8500 and 1/14,000 births and its prenatal diagnosis by US is difficult, with detection rates ranging from 7% to 22%. PRS is a heterogeneous condition with multiple different definitions used, being classically defined by a clinical triad including micrognathia (or retrognathia), glossoptosis, and posterior cleft palate.^[1]

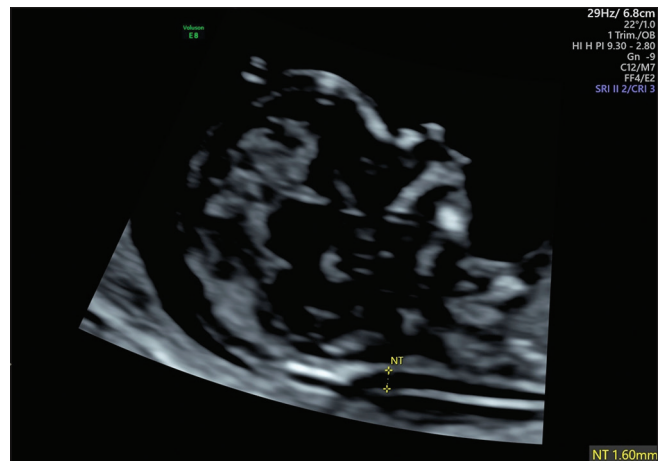


Figure 1: First-trimester ultrasound: midsagittal section of the fetal head raising suspicion for subtle retrognathia

Address for correspondence: Dr. Ana Portela Carvalho, Department of Obstetrics and Gynaecology, Centro Hospitalar do Tâmega e Sousa, Avenida do Hospital Padre Américo 210, 4564-007, Penafiel, Porto, Portugal.
E-mail: ana.sofia.portela.carvalho@gmail.com

Received: 26-10-2019 Revised: 25-11-2019 Accepted: 03-12-2019 Available Online: 28-01-2020

Access this article online

Quick Response Code:



Website:
www.jmuonline.org

DOI:
10.4103/JMU.JMU_103_19

This is an open access journal, and articles are distributed under the terms of the Creative Commons Attribution-NonCommercial-ShareAlike 4.0 License, which allows others to remix, tweak, and build upon the work non-commercially, as long as appropriate credit is given and the new creations are licensed under the identical terms.

For reprints contact: WKHLRPMedknow_reprints@wolterskluwer.com

How to cite this article: Carvalho AP, Estevinho C, Coelho M, Rocha J, Marinho C, Rodrigues G. Abnormal fetal profile at first-trimester ultrasound scan complicated by severe polyhydramnios at the second half of pregnancy. J Med Ultrasound 2021;29:65-7.

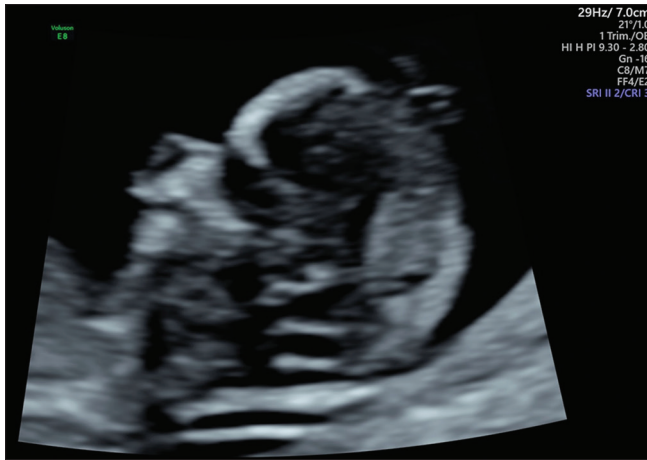

Figure 2: First-trimester ultrasound: parasagittal section of the fetal head with receding chin

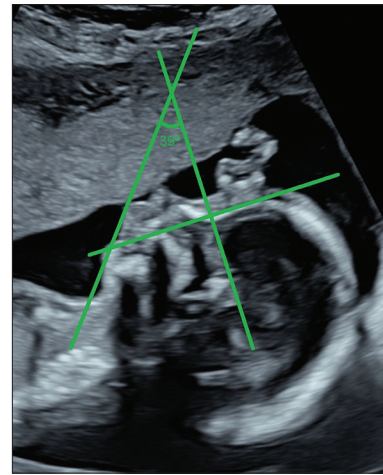

Figure 3: Mid-trimester ultrasound: inferior facial angle of 39° suggesting micrognathia

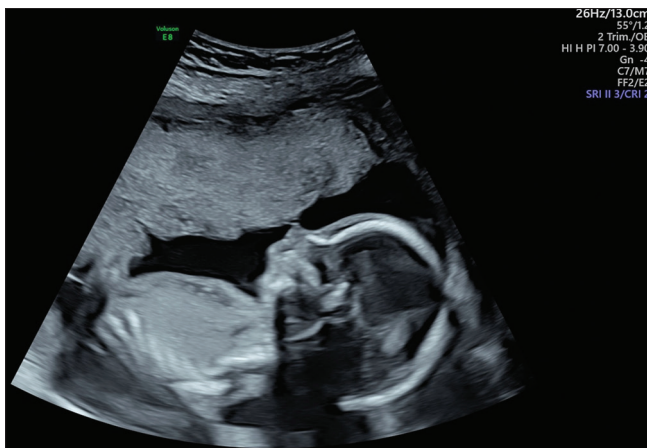

Figure 4: Mid-trimester ultrasound: glossoptosis as the tongue is displaced posteriorly

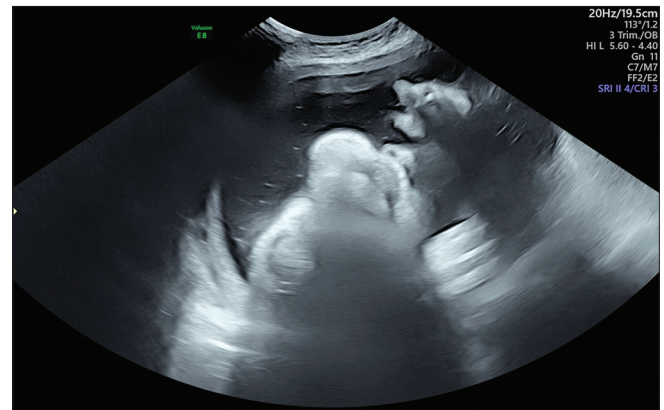


Figure 5: Mid-trimester ultrasound: integrity of the upper lip excluding cleft lip

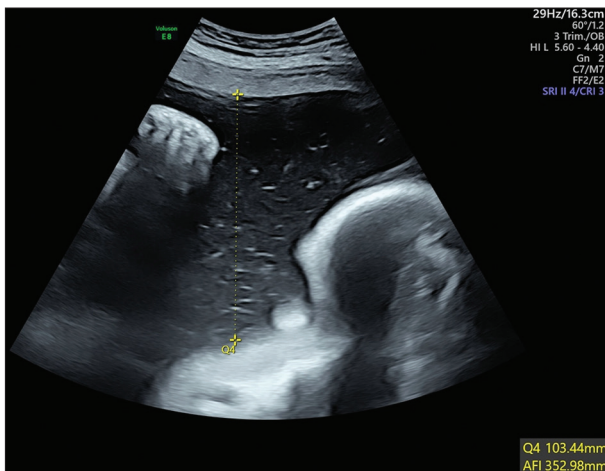


Figure 6: Third-trimester ultrasound: Polyhydramnios

Micrognathia is a rare US finding in which there is a small mandible. Retrognathia is defined as the abnormal receding position of the mandible in relation to the maxilla. In the majority of the situations, micrognathia and retrognathia are associated (microretrognathia) as a small mandible has, by

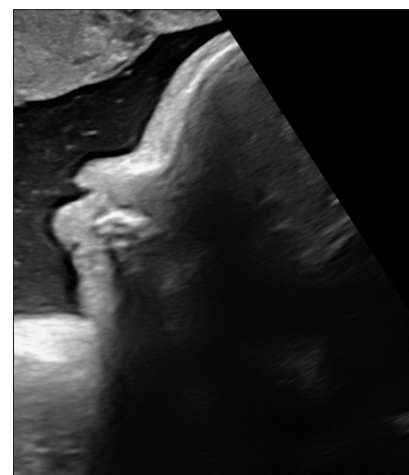


Figure 7: Third-trimester ultrasound: midsagittal section showing abnormal receding position of the chin in relation to the upper lip

definition, a receding position.^[2] Fetal micrognathia can be subjectively suspected in the midsagittal view of the face, but many studies have been published reporting multiple methods for its objective US diagnosis.^[3] Of notice, the inferior facial angle (IFA) is measured in a midsagittal view of the fetal profile at the cross section of a line orthogonal to the vertical part of

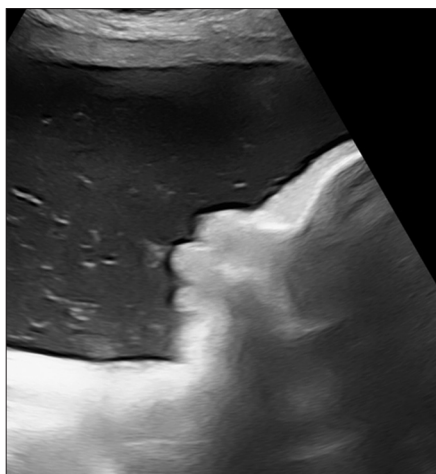


Figure 8: Third-trimester ultrasound: midsagittal section showing prominent upper lip

the forehead at the level of the nasofrontal suture and a line from the tip of the mentum to the anterior border of the more protrusive lip, being its normal value 65° .^[4] In this case, the finding of an IFA of 39° at the second-trimester US confirmed the first-trimester suspicion of microretrognathia.

Micrognathia may be triggered by adverse environmental factors (such as neuromuscular conditions, for example, fetal akinesia deformation sequence) or genetic factors. Chromosomal abnormalities, mainly trisomy 18 and triploidy, are found in 25%–35% of cases. Nonchromosomal genetic syndromes associated with micrognathia include PRS, Treacher Collins syndrome, and otocephaly.^[2,4,5]

The definite diagnosis of PRS should be suspected if micrognathia is an isolated finding with no cleft palate identified and especially if glossoptosis is also found and in the absence of chromosomal defects.^[6] Both micrognathia and macroglossia concur to cause the tongue to move upwards (glossoptosis), preventing the closure of the soft palate (resulting in cleft palate). Polyhydramnios is also frequently found in consequence of swallowing difficulty secondary to the obstruction caused by micrognathia and glossoptosis, however, it is nonspecific, as it is present in many other conditions.^[7] PRS can be an “isolated” in about 50% of the cases, having a low mortality rate and good developmental prognosis, “syndromic” (that is, associated with several malformations as part of a syndrome, especially central nervous system and skeletal anomalies), with higher mortality rate and poorer outcome or “associated” when the associated defects cannot be categorized as a syndrome and having a heterogeneous prognosis.^[1,8]

CONCLUSION

Microretrognathia remains the best hallmark for suspecting PRS in prenatal US, and the presence of glossoptosis is sufficient to confirm PRS even if the cleft palate is not clearly evident. Polyhydramnios is common in PRS, and its presence should prompt the evaluation of the fetal profile, palate, and

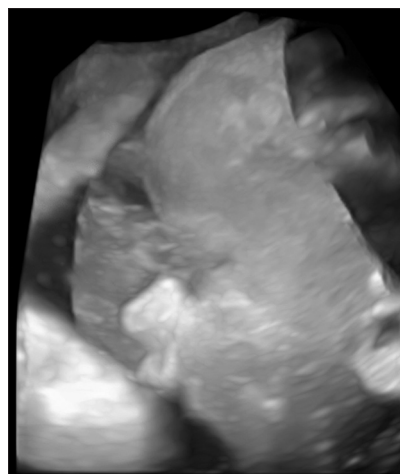


Figure 9: Third-trimester ultrasound: 3D reconstruction of the abnormal fetal profile highlighting the prominent upper lip and receding chin

tongue.^[1] In this case, no other malformations were identified and the postnatal cytogenetic testing was normal, allowing the diagnosis of isolated PRS.

This case highlights the importance of routine examination of the fetal profile from the first-trimester US.

Declaration of patient consent

The authors certify that they have obtained all appropriate patient consent forms. In the form the patient has given her consent for her images and other clinical information to be reported in the journal. The patient understands that her name and initials will not be published and due efforts will be made to conceal the identity, but anonymity cannot be guaranteed.

Financial support and sponsorship

Nil.

Conflicts of interest

There are no conflicts of interest.

REFERENCES

1. Lind K, Aubry MC, Belarbi N, Chalouhi C, Couly G, Benachi A, *et al.* Prenatal diagnosis of Pierre Robin sequence: Accuracy and ability to predict phenotype and functional severity. *Prenat Diagn* 2015;35:853-8.
2. Paladini D. Fetal micrognathia: Almost always an ominous finding. *Ultrasound Obstet Gynecol* 2010;35:377-84.
3. Rotten D, Levailant JM, Martinez H, Ducou le Pointe H, Vicaud E. The fetal mandible: A 2D and 3D sonographic approach to the diagnosis of retrognathia and micrognathia. *Ultrasound Obstet Gynecol* 2002;19:122-30.
4. Luedders DW, Bohlmann MK, Germer U, Axt-Flidner R, Gembruch U, Weichert J. Fetal micrognathia: Objective assessment and associated anomalies on prenatal sonogram. *Prenat Diagn* 2011;31:146-51.
5. Bromley B, Benacerraf BR. Fetal micrognathia: Associated anomalies and outcome. *J Ultrasound Med* 1994;13:529-33.
6. Bronshtein M, Blazer S, Zalel Y, Zimmer EZ. Ultrasonographic diagnosis of glossoptosis in fetuses with Pierre Robin sequence in early and mid pregnancy. *Am J Obstet Gynecol* 2005;193:1561-4.
7. Kaufman MG, Cassady CI, Hyman CH, Lee W, Watcha MF, Hippard HK, *et al.* Prenatal identification of Pierre Robin sequence: A review of the literature and look towards the future. *Fetal Diagn Ther* 2016;39:81-9.
8. Di Pasquo E, Amiel J, Roth P, Malan V, Lind K, Chalouhi C, *et al.* Efficiency of prenatal diagnosis in Pierre Robin sequence. *Prenat Diagn* 2017;37:1169-75.